

LOCAL TREATMENT OF A CONTAMINATED SKIN WOUND USING AN ORIGINAL DRUG COMBINATION AND MAGNETIC THERAPY IN AN EXPERIMENT

Terekhov AG , Pankrusheva TA, Chekmareva MS, Turenko EN, Artyushkova EB, Mishina ES, Grigoryan AYU, Myatechkin AA

Kursk State Medical University, Kursk, Russia

Currently, treatment of contaminated skin wounds aggravated by ischemia of superficial soft tissues is a problem that presents certain difficulties. The search for the new ways of treatment and drugs possessing a multidirectional effect is a relevant problem. In this study, we aimed to explore the peculiarities of wound evolution and the effectiveness of the designed combination of medicines and magnetic therapy in a contaminated skin wound case. For the experiment, we divided male Wistar rats into 3 groups and modeled a contaminated skin wound in each of the animals. In the first group, no treatment was performed, in the second, we used the developed combination (benzalkonium chloride, dexpanthenol, pentoxifylline and carboxymethylcellulose sodium salt, combined with magnetic therapy), in the third — ointment with dioxomethyltetrahydropyrimidine + chloramphenicol and magnetic therapy. Planimetry, acid-base balance registration, measurements of microhemocirculation and local temperature of the wound bed underpinned monitoring assessment of the wounds. At the end of the study, the wound area in the second group was 10.7 and 3.7 ($p < 0.05$) times smaller than in the first and third groups, respectively, and healing rate — 2.6 and 1.3 ($p < 0.05$) times faster. The maximum values of microhemocirculation and the lowest pH were registered in the second group. Thus, combination of drugs and magnetotherapy we designed promoted healing of a contaminated skin wound, which allows recommending this treatment method for further study at the preclinical level.

Keywords: contaminated wound, local wound treatment, benzalkonium chloride, pentoxifylline, wound process

Author contribution: Terekhov AG — study concept and design, analysis of the resulting data, editing; Pankrusheva TA — design of the drug combination, data collection; Chekmareva MS — design of the drug combination, data collection; Turenko EN — collection of material, statistical data processing, analysis of the resulting data, article preparation; Artyushkova EB — collection of material, analysis of the resulting data; Mishina ES — collection of material, statistical data processing, analysis of the resulting data; Grigoryan AYU — analysis of the resulting data, article preparation, editing; Myatechkin AA — analysis of the resulting data, article preparation, editing.


Compliance with the ethical standards: the study was approved by the Ethics Committee of the Kursk State Medical University (Minutes #7 of November 30, 2020). The series of animal experiments, the conditions of their detention met the requirements of the Strasbourg Convention for the Protection of Animal Rights (France, 1986) and GOST 33044-2014 Principles of good laboratory practice.

✉ **Correspondence should be addressed:** Alexey G. Terekhov
Karla Marxa, 3, Kursk, 305041, Russia; alexter4646@yandex.ru

Received: 09.11.2023 **Accepted:** 19.12.2023 **Published online:** 31.12.2023

DOI: 10.47183/mes.2023.065

МЕСТНОЕ ЛЕЧЕНИЕ КОНТАМИНИРОВАННОЙ КОЖНОЙ РАНЫ ОРИГИНАЛЬНОЙ ЛЕКАРСТВЕННОЙ КОМБИНАЦИЕЙ В СОЧЕТАНИИ С МАГНИТОТЕРАПИЕЙ В ЭКСПЕРИМЕНТЕ

А. Г. Терехов , Т. А. Панкрушева, М. С. Чекарева, Е. Н. Туренко, Е. Б. Артюшкова, Е. С. Мишина, А. Ю. Григорьян, А. А. Мятчин

Курский государственный медицинский университет Минздрава России, Курск, Россия

Лечение контаминированных ран кожи в условиях ишемии поверхностных мягких тканей в современном мире — это проблема, которая представляет определенные трудности. Актуален поиск новых способов и средств лечения, обладающих мультинаправленным действием. Целью исследования было изучить особенности течения раневого процесса и эффективности воздействия на контаминированную кожную рану сочетанного применения разработанной комбинации. Экспериментальную работу проводили на трех группах крыс-самцов породы «Вистар», которым моделировали контаминированную кожную рану. В первой группе лечение не проводили, во второй использовали разработанную комбинацию — бензалкония хлорид, декспантенол, пентоксифиллин и натриевую соль карбоксиметилцеллюлозы, в сочетании с магнитотерапией, в третьей — мазь с диоксометилтетрагидропиримидином + хлорамфениколом и магнитотерапией. Для оценки течения раневого процесса использовали планиметрический метод, определяли кислотно-щелочной баланс, показатели микрогемодикуляции и локальной температуры раневого ложа. По завершению исследования площадь ран во второй группе была меньше, чем в первой и третьей в 10,7 и 3,7 ($p < 0,05$) раза. Скорость заживления выше во второй группе — в 2,6 и 1,3 ($p < 0,05$) раза. Максимальные показатели микрогемодикуляции и наименьшие значения pH отмечали во второй группе. Таким образом, сочетанное применение разработанной нами лекарственной комбинации и магнитотерапии благоприятно влияло на процесс заживления контаминированной кожной раны, что позволяет рекомендовать данный способ лечения для дальнейшего изучения на доклиническом уровне.

Ключевые слова: контаминированная рана, местное лечение ран, бензалкония хлорид, пентоксифиллин, раневой процесс

Вклад авторов: А. Г. Терехов — разработка концепции и дизайна исследования, анализ полученных данных, редактирование; Т. А. Панкрушева — разработка лекарственной комбинации, сбор данных; М. С. Чекарева — разработка лекарственной комбинации, сбор данных; Е. Н. Туренко — сбор материала, статистическая обработка данных, анализ полученных данных, подготовка текста; Е. Б. Артюшкова — сбор материала, анализ полученных данных; Е. С. Мишина — сбор материала, статистическая обработка данных, анализ полученных данных; А. Ю. Григорьян — анализ полученных данных, подготовка текста, редактирование; А. А. Мятчин — анализ полученных данных, подготовка текста, редактирование.

Соблюдение этических стандартов: исследование было одобрено этическим комитетом «Курский государственный медицинский университет» Министерства здравоохранения Российской Федерации (протокол № 7 от 30 ноября 2020 г.). Серии экспериментов, проведенные на животных, условия их содержания соответствовали принципам Страсбургской конвенции по защите прав животных (Франция, 1986) и ГОСТу 33044-2014 «Принципы надлежащей лабораторной практики».

✉ **Для корреспонденции:** Алексей Геннадьевич Терехов
ул. Карла Маркса, д. 3, г. Курск, 305041, Россия; alexter4646@yandex.ru

Статья получена: 09.11.2023 **Статья принята к печати:** 19.12.2023 **Опубликована онлайн:** 31.12.2023

DOI: 10.47183/mes.2023.065

Currently, treatment of a contaminated wound is a rather complex problem for a medical professional practicing surgery. Chronic wounds associated with diabetes mellitus, chronic arterial insufficiency, translate into disability of patients, cosmetic defects, and also create conditions for the spread of infection, thus increasing the threat of ulcerative necrotic process, subsequent gangrene and amputation [1]. In economically developed countries, the number of limb amputations varies from 13.7 to 32.3 for every 100,000 people, with 50% of amputees dying within the first year thereafter, which underpins the urgency of this problem [2, 3]. This group of patients needs inpatient treatment. Open wounds require dressings that prevent entry of microorganisms thereinto, and contain no components that have toxic, allergic, mutagenic, and carcinogenic effects [4]. Considering the methods of treatment, a practitioner should look for shorter healing time, prevention of complications, and scar tissue esthetics. These criteria substantiate the search for new techniques, development of drug combinations and a balance between medicinal and physiotherapeutic parts of wound treatment [4].

Thus, the question of creating a new multicomponent drug combination that will meet all the above requirements takes priority. Sodium salt of carboxymethylcellulose (Na-CMC), on which the active substances are immobilized, can be the basis thereof. As reported in the literature, Na-CMC is the base for films that accelerate formation and maturation of new tissue, influence fibrillogenesis, and also markedly stimulate reparative processes in the infected skin wounds [5]. Na-CMC-based gels are used to prevent intraoperative drying of peritoneum and formation of postoperative commissures in the context of operations on organs with a serous coating [6].

It is feasible to augment the combination with a component that enhances skin regeneration. One of these is dexpanthenol; this drug, applied topically, turns into pantothenic acid, which, in turn, is part of coenzyme A. All oxidoreductases require a coenzyme: redox processes are impossible without it. Dexpanthenol enhances epidermal differentiation and proliferation of dermal fibroblasts, thereby supporting skin regeneration [7]. Therefore, there have been designed various topical preparations containing this compound, widely used in dermatology. Topically, dexpanthenol is also recommended in cases of small and superficial wounds [8].

The preferred antiseptic should be bactericidal, since pathogenic microflora is less likely to grow resistant thereto; one of the proven agents of this kind is benzalkonium chloride. It reduces surface tension between two media and attracts negatively charged particles, thus disrupting integrity of the cell membranes, upsetting denaturation of intracellular proteins, and disordering metabolic processes in the cells, which triggers release of vital elements into intercellular space and ultimately eliminates the microorganisms [9].

Since we are considering healing of a contaminated wound, it seems promising to complete the combination with a component that improves microcirculation in the tissues, such as pentoxifylline. Previous studies confirm that pentoxifylline improves blood's rheological parameters by reducing the viscosity plasma and whole blood, increasing the elasticity of erythrocyte membranes and suppressing erythrocyte aggregation, and reducing platelet aggregation. The compound also possesses anti-inflammatory and antioxidant properties [10]. To boost healing, many researchers recommend extending the treatment protocol with physical factors, such as magnetotherapy, since an external magnetic field supports targeted delivery of the therapeutic nanocomplex and helps maintain concentration of the drug in the wound at the optimal level [10, 11].

Therefore, this study aimed to investigate the specifics of the wound process and the efficacy of the combination of benzalkonium chloride, dexpanthenol, pentoxifylline, and magnetic therapy on contaminated skin.

METHODS

The study included *in vivo* experiments on 90 white male Wistar rats. The animals were allocated into 3 groups ($n = 30$). The weight of each rat was 180.0 ± 20.0 g. All animals received inhalation anesthesia in a sterile operating room at the Laboratory of Experimental Surgery and Oncology of the Experimental Medicine Research Institute, and had a contaminated skin wound modeled (ischemic conditions) by our proprietary method (patent decision 2023124868/14, invention "Method for modeling a skin wound in ischemic conditions").

Wound modeling required access to the femoral neurovascular bundle on the medial surface of the thigh under inguinal ligament. Using 4/0 catgut, we ligated a. femoralis and resected 1/3 of its trunk distally from the inguinal ligament. Seven days 7 days after resection, on a shaved patch of skin, after applying an antiseptic solution and hydrotreating the field with 0.9% NaCl solution (5 ml), we excised a 14 mm round skin flap (down to the superficial fascia) in the middle third of the anterolateral surface of the thigh. After hemostasis, the wound was covered with an aseptic dressing. For 4 days, the wound was not treated, dressed with a Cosmopor bandage with the absorbent pad removed, which created conditions for its contamination. To standardize the treatment process, a special protective collar for rats was put on animals. The rats were kept in individual boxes (cages) to prevent contact between them, and ate the same standard diet. The bedding was replaced once a day in all cages. On the 5th day after the excision, we started treatment, which was when the experiment was considered launched. The presence of a contaminated wound formed under ischemic conditions was confirmed by microbiological examination and laser Doppler fluorometry of the affected limb.

Study groups:

Group 1 — control group, no treatment;

Group 2 — treatment with a combination of benzalkonium chloride + dexpanthenol + pentoxifylline (topically) + NaCMC + magnetic therapy;

Group 3 — treatment with an dioxomethyltetrahydropyrimidine ointment + chloramphenicol ointment combined with magnetic therapy.

According to the register of medicines, dioxomethyltetrahydropyrimidine + chloramphenicol ointment has anti-inflammatory and antimicrobial effects; it combats gram-positive and gram-negative microorganisms, easily penetrates deep into the tissues without damaging biological membranes, and stimulates regeneration. Its antibacterial effect persists in the presence of pus and necrotic masses. This ointment is widely used in outpatient practice.

Combinations of drugs and physiotherapeutic methods of treatment:

1) benzalkonium chloride 0.02 g + dexpanthenol 5 g + 2% pentoxifylline solution up to 100 g (topically) + NaCMC 4.0 g and magnetotherapy;

2) dioxomethyltetrahydropyrimidine ointment + chloramphenicol and magnetotherapy.

Second group received 0.5 ml of the respective gel to the wound and magnetotherapy in the given mode; in the third group, it was 0.5 ml of the dioxomethyltetrahydropyrimidine ointment + chloramphenicol and magnetotherapy. For the

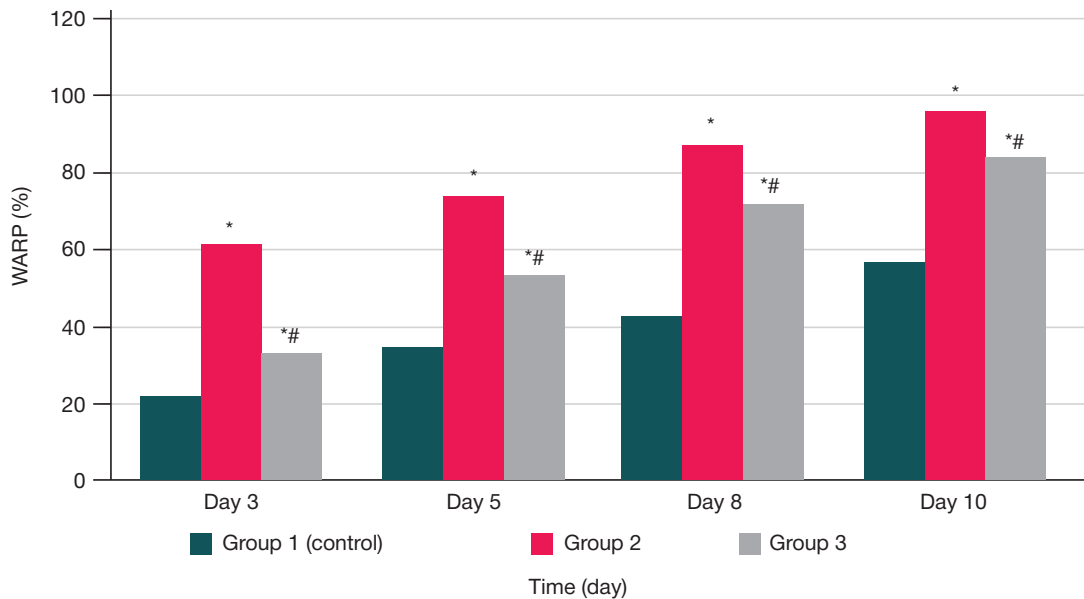


Fig. 1. Wound area reduction percentage (%), Me (25; 75). * — $p < 0.05$ in comparison of group 1 (control) and other groups; # — $p < 0.05$ in comparison of group 2 and group 3.

latter, we used Milta-F-8-01 (Binom; Russia) (GOST25052-87) magnetic, IR, and laser therapy device in the magnetotherapy mode. The frequencies used were 80, 150, 300, 600, 1500, 5000 Hz; power — 50 MW; session duration — 6 min (1 min at each frequency), conducted once a day.

The treatment protocol implied daily dressings in sterile conditions for 10 days, the bandages carrying the above combinations.

We used Lesion Meter planimetry software to monitor the progress.

The percentage of wound area reduction was calculated from the initial size by the following formula:

$$\text{WARP} = \frac{S_0 - S}{S_0} \times 100\%,$$

where WARP is the wound area reduction percentage, S_0 the initial average wound area at the beginning of treatment, mm^2 , and S the average wound area at the time of measurement, mm^2 .

The rate of wound healing was calculated by the following formula:

$$\text{HR} = \frac{\text{WARP}_1 - \text{WARP}_0}{T},$$

where HR is the healing rate, WARP_1 is the wound area reduction percentage (compared to the initial size) at the time of measurement, WARP_0 the wound area reduction percentage at the previous measurement, and T the number of days between measurements.

To monitor microcirculation in the wound and the surrounding tissue, we employed laser Doppler flowmetry (LDF), with LDF100C laser Doppler flow module (Biopac system Inc.; USA) and TSD-144 probe taking measurements, and Acq Knowledge 4.2 for MP150 doing the processing. The acid-base balance was determined by recording the pH values on the wound surface using a PH98110 pH meter (Kelilong; China), and local temperature was taken with the help of a WF-5000 infrared thermometer (B.Well; Switzerland) [12, 13].

The results of the experimental study were recorded on the 1st, 3rd, 5th, 8th, and 10th day. For statistical processing thereof, we used Microsoft Excel 2014 and Statistica 13.0 software. Quantitative attributes were given as median, 25th and 75th percentiles (Me (25; 75)). For statistical analysis, we applied

the Kruskal–Wallis test to the results, and compared the mean ranks by groups. The differences were considered statistically significant at $p < 0.05$.

RESULTS

Planimetry showed that on the first day, WARP was similar in all three groups studied. It was gradually decreasing through the experiment; in group 2, WARP was the largest among the three groups already on the 3rd day, with the differences being significant (Fig. 1). Overall, on the 3rd day, the figures were as follows: group 1 — (21.26 (20.6; 25.19) %), group 2 — (61.54 (57.47; 65.77) %), group 3 — (33.18 (30.6; 36.36) %). Thus, in absolute values, WARP in group 2 was 2.9 times greater than in group 1 and 1.8 times greater than in group 3. On the 5th day, the difference, remaining significant, was as follows: group 1 — (34.69 (28.13; 39.87) %) and 1.4 times more than in group 3 (53.33 (47.85; 55.77) %). By the end of the experiment, on the 10th day, WARP in group 2 was (95.74 (89.45; 99.92) %), in group 1 — (56.22 (54.53; 61.91) %), in group 3 — (84.59 (73.35; 86.78) %); the differences were significant, with the values in group 2 1.7 and 1.1 times greater than in group 1 and group 3, respectively.

The data in Table 1 indicate that during the first 3 days, healing rate in group 2 was significantly higher than in group 1 and group 3 (2.2-fold and 1.4-fold, respectively). Group 2 keeps its leadership during days 5 through 8, with healing rate there 2.8 and 1.3 times greater than in groups 1 and 3, respectively. By the end of the experiment, during days 8 through 10, the differences, still significant, were 1.9 times and 1.2 times (group 2 vs. group 1 and group 3, respectively).

Weighted average LDF values (surfaces of the wounds) of group 2 were significantly different from those of groups 1 and 3 on the 3rd, 5th, 8th, and 10th day of the experiment (Fig. 2). In terms of perfusion units (p.u.), on the 3rd day, the values in group 2 were (304.74 (288.21; 320.1)), which is 1.2 and 1.03 times more than in groups 1 (253.18 (245.39; 260.27) p.u.) and the 3 (293.77 (278.51; 307.01) p.u.). Data for the 5th day: group 1 (269.26 (263.15; 275.79) p.u.), group 2 (371.69 (366.58; 377.17) p.u.), group 3 (341.07 (334.61; 345.88) p.u.). Thus, the values registered in group 2 are 1.4 and 1.08 times higher

Table 1. Dynamics of wound healing in the treated experimental animals, Me (25; 75)

Group	Healing rate, %/day			
	Days 1–3	Days 3–5	Days 5–8	Days 8–10
	<i>n</i> = 24	<i>n</i> = 18	<i>n</i> = 12	<i>n</i> = 6
Group 1 (control)	9.05 (7.75; 2.66)	5.17 (3.66; 7.93)	2.61 (1.90; 3.19)	3.52 (2.74; 3.88)
Group 2	20.38 (18.80; 22.67)*	15.99 (11.99; 16.11)*	8.70 (6.98; 9.46)*	7.02 (4.91; 8.2)*
Group 3	14.22 (11.39; 15.32)**	11.96 (6.73; 11.38)**	6.66 (3.69; 8.56)**	5.91 (3.85; 9.14)**

Note: * — $p < 0.05$ in comparison of group 1 (control) and other groups; ** — $p < 0.05$ in comparison of group 2 and group 3.

than in groups 2 and 3. On the 8th day, the difference in the LDF value between group 1 (289.18 (284.97; 292.76) p.u.) and group 2 (461.17 (457.33; 463.07) p.u.) was 1.6 times, between group 1 and group 3 (403.84 (399.66; 407.39) p.u.) — 1.1 times. By the end of the experiment, on the 10th day, the value in group 2 (505.11 (499.29; 511.71) p.u.) was significantly higher than in group 1 (301.45 (296.23; 307.01) p.u.) and group 3 (436.93 (431.59; 443.34) p.u.), by 1.7 and 1.1 times, respectively.

The analysis of the wound acid-base balance data reveals that on days 3, 5, 8, and 10, the respective value in group 2 was significantly lower than in groups 1 and 3 ($p < 0.05$) (Table 2). On the 3rd day, the difference was 1.2 times 1.1 times (group 2 vs. group 1 and group 2 vs. group 3, respectively). The dynamics persisted through day 5. In comparison of the groups, the lowest pH values were registered in group 2, the greatest significant difference recorded on the 10th day: by 1.4 and 1.3 times for groups 1 and 3, respectively.

Wound bed thermometry revealed no differences between the groups on the 1st day of the experiment (Fig. 3). On the 3rd day of treatment, local temperature was the lowest in groups 2 (34.15 (33.6; 34.5) °C) and 3 (33.95 (33.7; 34.3) °C); the difference with the control group (35.25 (35.1; 36.05) °C) was significant, and equaled 1.03 times for both groups. On the 8th day, the difference between group 1 (37.85 (37.5; 38.8) °C) and groups 2 and 3 was still 1.03 times: (36.55 (36.45; 36.8) °C) in group 2, and (36.83 (35.45; 37.3) °C) in group 3, by 1.03 times. Thus, the progress in the control group was the weakest. Moreover, on the 10th day, the difference increased to 1.2 times compared to the 1st day (38.92 (38.3; 39.3) °C vs. (33.75 (33.2; 34.3) °C).

DISCUSSION

Planimetry data shows that significantly higher values were registered in group 2 on all days of the experiment. As for the healing rate, on days 1 through 5, this indicator was greater in group 2 than in groups 1 and 3 by 2.6 and 1.4 times, respectively.

LDF values were also highest in group 2: 1.3 and 1.2 times higher than in groups 1 and 3, respectively, which means the wounds in group 2 had the best local blood microcirculation. In terms of pH, the values in group 2 were significantly better than in groups 1 and 3 on days 3 through 10, which indicated development of an acidic environment that adversely affects pathogenic microorganisms. Local temperature was significantly lowest in groups 2 and 3, compared to the control, on days 8 and 10; moreover, in group 1, wound bed temperature was steadily increasing, which may have indicated a pronounced inflammatory process.

Reports by other authors are consistent with our findings: the components we used in the combination effectively accelerate the processes associated with wound healing.

Thus, topical pentoxifylline improved local blood flow in the injured tissue, which boosted healing [14]. It was also proven effective against burn wounds [15]. A randomized prospective clinical trial confirmed beneficial effects of a dexpanthenol ointment applied to skin damaged as a result of fractional ablative CO₂ laser resurfacing. The authors found that in dry skin, dexpanthenol can compensate, to some extent, for low hydration by increasing the water content and producing a positive effect on the molecular mobility of lipid layers and stratum corneum proteins [16]. A number of authors have investigated the physico-chemical properties and therapeutic effect of benzalkonium chloride. This antiseptic was found to possess a pronounced antimicrobial powers not only against pathogenic bacteria, but also *Candida* fungi [17]. Another group investigated the effect of benzalkonium chloride carried by polyethylene oxide on the purulent-inflammatory process in soft tissues; the results confirmed that this antiseptic accelerates healing rate of the skin defect in the first phase of the wound process [18].

There have also been conducted studies looking into the benefits of magnetotherapy in the context of wound healing. One has established that a pulsed electromagnetic field applied to patients with diabetic angiopathy accelerated wound healing by 1.5 times [19]. Another reported a positive effect of therapeutic magnetic resonance on the healing of trophic

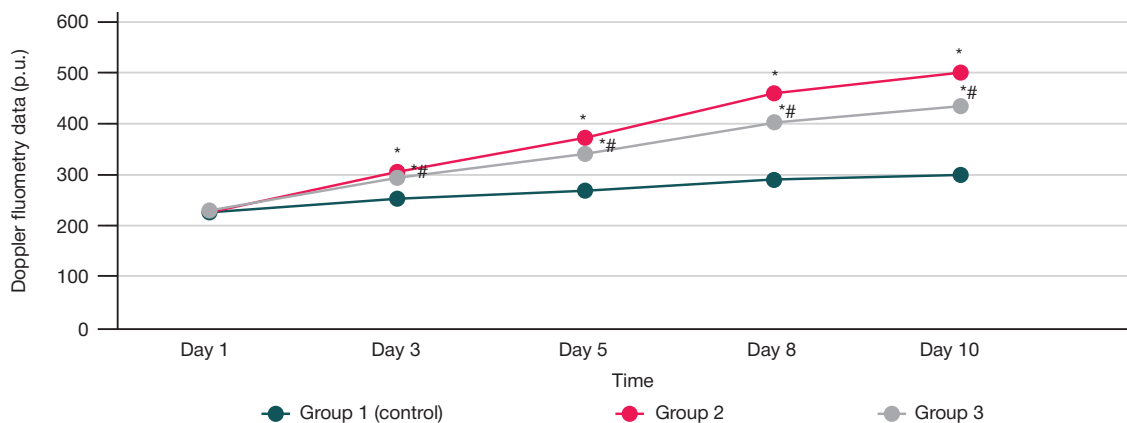


Fig. 2. Laser Doppler flowmetry dynamics (p.u.), Me (25; 75). * — $p < 0.05$ in comparison of group 1 (control) and other groups; # — $p < 0.05$ in comparison of group 2 and group 3

Table 2. Wound pH changes, Me (25; 75)

Group	Day 1 <i>n</i> = 30	Day 3 <i>n</i> = 24	Day 5 <i>n</i> = 18	Day 8 <i>n</i> = 12	Day 10 <i>n</i> = 6
Group 1 (control)	7.7 (7.54; 7.91)	7.54 (7.38; 7.71)	7.22 (7.18; 7.36)	7.275 (7.18; 7.36)	7.22 (7.11; 7.32)
Group 2	7.56 (7.02; 7.45)	6.5 (6.55; 6.83)*	6.28 (6.33; 6.512)*	5.42 (5.55; 6.245)*	5.01 (4.82; 5.95) *
Group 3	7.63 (7.54; 7.99)	7.33 (7.20; 7.37)#	7.27 (6.93; 7.52)#	6.83 (6.55; 6.935)#	6.58 (6.43; 6.84) *#

Note: * — $p < 0.05$ in comparison of group 1 (control) and other groups; # — $p < 0.05$ in comparison of group 2 and group 3.

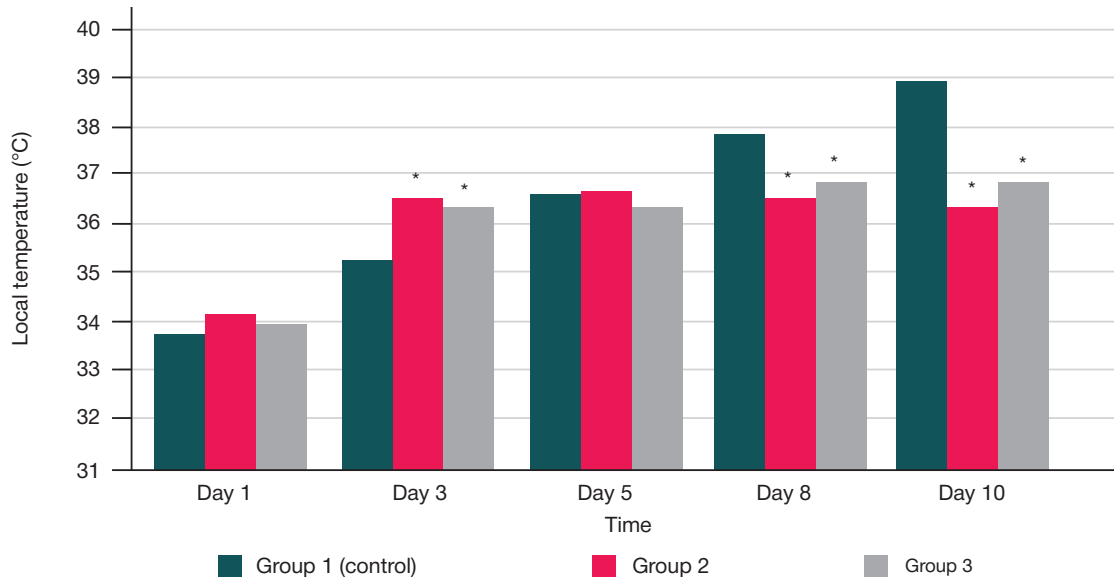


Fig. 3. Local wound temperature dynamics (°C), Me (25; 75); * — $p < 0.05$ in comparison of group 1 (control) and other groups; # — $p < 0.05$ in comparison of group 2 and group 3

ulcers, which took 44 days in the experimental group and 97 days in the control group [20].

CONCLUSIONS

Based on the planimetry, wound microhemocirculation, acid-base balance, wound bed thermometry data

collected in this study, we can conclude that the wounds healed in the most efficient way in group 2, where the treatment was by the method we suggested. Therefore, in the context of treatment of contaminated skin wounds, we can recommend further research of the combination of benzalkonium chloride + dexpanthenol + NaCMC + pentoxifylline + magnetotherapy.

References

- Markov SN, Spiridonov AA, Slepov AV. The possibility of using autologous adipose tissue for the stage shin wound closing. *Wounds and wound infections. The Prof. BM Kostyuchenok Journal.* 2021; 8 (3): 46–51. Russian.
- Kulikovich JK, LyzikovAA, Kaplan ML, Kovalenko AA, Usiankova VV. Long-term results of profundoplasty in patients with atherosclerotic lesions of the arteries of the lower extremities, depending on the state of the distal bed. *Health and Ecology Issues.* 2023; 20 (3): 46–52. Russian.
- Mansur HJ, Gatea FK. Effects of Topical Pentoxifylline on Induced Thermal Burn in Mice. *International Journal of Pharmaceutical Quality Assurance.* 2021; 12 (3): 299–305. DOI: 10.25258/ijpqa.12.3.26.
- Korolev DV, Shumatov VB, Plekhova NG. Local treatment of infected wounds depending on the phase of the wound process. *Health & education millennium.* 2023; 25 (7): 69–75. Russian.
- Shurshina AS, Kulish EI. Study of the diffusion process in films sodium salt of carboxymethyl cellulose — drug. *Izvestiya of Saratov University. Chemistry. Biology. Ecology.* 2021; 21 (4): 382–90. Russian.
- Lipatov VA, Kudryavtseva TN, Severinov DA. Application of cellulose derivatives in experimental surgery of parenchymal organs. *Science of the young (Eruditio Juvenium).* 2020; 8 (2): 269–83. DOI: 10.23888/hmj202082269-283. Russian.
- Proksch E, Berardesca E, Misery L, Engblom J, Bouwstra J. Dry Skin Management: Practical Approach in Light of Latest Research on Skin Structure and Function. *J Dermatolog Treat.* 2020; 31 (7): 716–22. DOI: 10.1080/09546634.2019.1607024.
- Jean-Yves Maillard. Impact of benzalkonium chloride, benzethonium chloride and chloroxylenol on bacterial antimicrobial resistance. *Journal of Applied Microbiology.* 2022; 133 (6): 3322–46.
- Dion MW, Hussey DH, Osborne JW. The effect of pentoxifylline on early and late radiation injury following fractionated irradiation in C3H mice. *Int J Radiat Oncol Biol Phys.* 1989; 17 (1): 101–7. DOI: 10.1016/0360-3016(89)90376-3. PMID: 2745184.
- Chupin AV, Pizova NV, Korshunov DA. Pentoxifylline in vascular pathology. *RMJ.* 2023; 3: 15–20. Russian.
- Bogatikov AA, Dobretsov KG, Melikhova MV, Rozhko MA, Lapina NV, Stolyar SV, et al. A new method for treating burn wounds using targeted delivery of medicinal substances by magnetic nanocarrier (experimental part). *J. Sib. Fed. Univ. Biol.* 2022; 15 (3): 422–36. Russian.
- Shanmugaraj K, Keerthanaa B. Influence of Autologous Platelet Concentrates on the Dynamics of Regenerative Processes in

- Treatment of Trophic Ulcers of Lower Extremities. *Indian Journal of Public Health*. 2019; 10 (11): 1851.
13. Vasilev PV, Margaryants NB, Erofeev NP. Laser doppler flowmetry in the microlymphodynamics study. *Sovremennye tehnologii v medicine*. 2019; 11 (2): 92–7. Russian.
 14. Aghajani A, Kazemi T, Enayatifard R, Amiri FT, Narenji M. Investigating the skin penetration and wound healing properties of niosomal pentoxifylline cream. *Eur J Pharm Sci*. 2020; 151: 105434.
 15. Moreira VM, et al. Pentoxifylline/Chitosan Films on Wound Healing: In Vitro/In Vivo Evaluation. *Pharmaceutics*. 2023; 15 (4): 1122.
 16. Grigoryan AY, Bezhin AI, Pankrusheva TA, Zhilyaeva LV, Mishina ES. Selection of the optimal basis for combination with benzalkonium chloride for the treatment of purulent wounds (experimental study). *Journal of New Medical Technologies*. 2021; 28 (2): 35–9. Russian.
 17. Shutov YuM, Shumkov OA, Veryatin YaA. Evaluation of the stimulating effect of platelet-enriched autoplasm and optimization of the resorption function of the lymphatic system on the healing of a trophic ulcer of venous etiology. *Medicine. Sociology. Philosophy. Applied research*. 2023; 1: 15–23. Russian.
 18. Bezhin AI, Lipatov VA, Fronchek EV, et al. Application chitosan-collagen complex nano-particles of silver and chymotrypsin in the treatment of purulent necrotic wounds. *Journal of New Medical Technologies*. 2019; 26 (3): 23–8. DOI: 10.21626/vestnik/2019-2/01. Russian.
 19. Amareswari VH, Padma K, Dharmarajan P, Shivakumar S, Dhillip KS. Evaluation of Efficacy of Pulsed Electromagnetic Field Therapy as an Adjuvant Therapy in Healing of Diabetic Foot Ulcers. *International Journal of Physiology*. 2020; 8 (2): 6–12. DOI: 10.37506/ijop.v8i2.1234.
 20. Dixit S, Ahmad I, Gular K, Eid RA, Reddy RS, Ribeiro IL, et al. Efficacy of single versus multiple exposure by electromagnetic modalities on gram-negative and positive bacterial strains in an in-vitro model. *Saudi J Biol Sci*. 2021; 28 (3): 1678–86. DOI: 10.1016/j.sjbs.2020.12.004.

Литература

1. Марков С. Н., Спиридонов А. А., Слепов А. В. Возможность применения жировой аутооткани для этапного закрытия раны голени. Раны и раневые инфекции. *Журнал имени профессора Б. М. Костюченко*. 2021; 8 (3): 46–51.
2. Куликович Ю. К., Лызинов А. А., Каплан М. Л., Коваленко А. А., Усенкова В. В. Отдаленные результаты профундопластики у пациентов с атеросклеротическим поражением артерий нижних конечностей в зависимости от состояния дистального русла. *Проблемы здоровья и экологии*. 2023; 20 (3): 46–52.
3. Mansur HJ, Gatea FK. Effects of Topical Pentoxifylline on Induced Thermal Burn in Mice. *International Journal of Pharmaceutical Quality Assurance*. 2021; 12 (3): 299–305. DOI: 10.25258/ijpqa.12.3.26.
4. Королёв Д. В., Плехова Н. Г., Шуматов В. Б. Местное лечение инфицированных ран в зависимости от фазы раневого процесса. *Здоровье и образование в XXI веке*. 2023; 25 (7): 69–75.
5. Шуршина А. С., Кулиш Е. И. Изучение процесса диффузии в пленках натриевая соль карбоксиметилцеллюлозы — лекарственное вещество. *Изв. Саратов. ун-та Нов. сер. Сер. Химия. Биология. Экология*. 2021; 21 (4): 382–90.
6. Липатов В. А., Кудрявцева Т. Н., Северинов Д. А. Применение карбоксиметилцеллюлозы в экспериментальной хирургии паренхиматозных органов. *Наука молодых – Eruditio Juvenium*. 2020; 8 (2): 269–83. DOI: 10.23888/hmj202082269-283.
7. Proksch E, Berardesca E, Misery L, Engblom J, Bouwstra J. Dry Skin Management: Practical Approach in Light of Latest Research on Skin Structure and Function. *J Dermatolog Treat*. 2020; 31 (7): 716–22. DOI: 10.1080/09546634.2019.1607024.
8. Jean-Yves Maillard. Impact of benzalkonium chloride, benzethonium chloride and chloroxylenol on bacterial antimicrobial resistance. *Journal of Applied Microbiology*. 2022; 133 (6): 3322–46.
9. Dion MW, Hussey DH, Osborne JW. The effect of pentoxifylline on early and late radiation injury following fractionated irradiation in C3H mice. *Int J Radiat Oncol Biol Phys*. 1989; 17 (1): 101–7. DOI: 10.1016/0360-3016(89)90376-3. PMID: 2745184.
10. Чупин А. В., Пизова Н. В., Коршунов Д. А. Пентоксифиллин при сосудистой патологии. *РМЖ*. 2023; 3: 15–20.
11. Богатиков А. А., Добрецов К. Г., Мелихова М. В., Рожко М. А., Лапина Н. В., Столяр С. В. и др. Новый способ лечения ожоговых ран с помощью адресной доставки лекарственных веществ магнитным наноносителем (экспериментальная часть). *Журнал СФУ. Биология*. 2022; 15 (3): 422–36.
12. Shanmugaraj K, Keerthanaa V. Influence of Autologous Platelet Concentrates on the Dynamics of Regenerative Processes in Treatment of Trophic Ulcers of Lower Extremities. *Indian Journal of Public Health*. 2019; 10 (11): 1851.
13. Васильев П. В., Маргарянц Н. Б., Ерофеев Н. П. Лазерная доплеровская флоуметрия в исследовании микролимфодинамики. *Современные технологии в медицине*. 2019; 11 (2): 92–7.
14. Aghajani A, Kazemi T, Enayatifard R, Amiri FT, Narenji M. Investigating the skin penetration and wound healing properties of niosomal pentoxifylline cream. *Eur J Pharm Sci*. 2020; 151: 105434.
15. Moreira VM, et al. Pentoxifylline/Chitosan Films on Wound Healing: In Vitro/In Vivo Evaluation. *Pharmaceutics*. 2023; 15 (4): 1122.
16. Григорьян А. Ю., Бежин А. И., Панкрушева Т. А., Жилияева Л. В., Мишина Е. С. Выбор оптимальной основы для комбинации с бензалкония хлоридом для лечения гнойных ран (экспериментальное исследование). *ВНМТ*. 2021; 28 (2): 35–9.
17. Шутов Ю. М., Шумков О. А., Верятин Я. А. Оценка стимулирующего влияния обогащенной тромбоцитами аутоплазмы и оптимизации резорбционной функции лимфатической системы на заживление трофической язвы венозной этиологии. *Медицина. Социология. Философия. Прикладные исследования*. 2023; 1: 15–23.
18. Бежин А. И., Липатов В.А., Фрончек Э. В. и др. Применение хитозан-коллагенового комплекса с нано-частицами серебра и химотрипсином в лечении гнойно-некротических ран. *Вестник новых медицинских технологий*. 2019; 26 (3): 23–8. DOI: 10.21626/vestnik/2019-2/01.
19. Amareswari VH, Padma K, Dharmarajan P, Shivakumar S, Dhillip KS. Evaluation of Efficacy of Pulsed Electromagnetic Field Therapy as an Adjuvant Therapy in Healing of Diabetic Foot Ulcers. *International Journal of Physiology*. 2020; 8 (2): 6–12. DOI: 10.37506/ijop.v8i2.1234.
20. Dixit S, Ahmad I, Gular K, Eid RA, Reddy RS, Ribeiro IL, et al. Efficacy of single versus multiple exposure by electromagnetic modalities on gram-negative and positive bacterial strains in an in-vitro model. *Saudi J Biol Sci*. 2021; 28 (3): 1678–86. DOI: 10.1016/j.sjbs.2020.12.004.